



PATIENT

Teddy Pereira

PRESENTING CLINICAL SIGNS

History: New murmur. Panting at rest.

SPECIES

Canine

ELECTROCARDIOGRAPHIC FINDINGS *Note: Single lead ECGs are evaluated as a rhythm strip. Morphology/MEA cannot be definitively commented on.

A single lead ECG is available; 50mm/s, 20mm/mV. The average heart rate is 125bpm (range 100-150bpm). P waves are difficult to identify throughout; however, a sinus origin is suspected. P for every QRS complex and vice versa. The P morphology is positive. The QRS is low voltage.

BREED

Australian Shepherd

No ectopic beats, pauses or other dysrhythmias observed.

ECG diagnosis: Normal sinus rhythm with respiratory variation.

SEX

Male Neutered

ECHOCARDIOGRAM FINDINGS *Limited imaging window

2D, m-mode, color flow and doppler imaging is available. The mitral valve is diffusely thickened with minimal prolapse into the left atrial lumen. There is severe eccentric mitral regurgitation present. There is severe left atrial enlargement. There is mild left ventricular dilation. Left ventricular systolic function is hyperdynamic. Mild right atrial and ventricular dilation (subjective). Mild thickening of the tricuspid valve with no TR. There is normal systolic flow velocity across the aortic valve. The aortic valve appears trileaflet with normal mobility. The main pulmonary artery is normal in diameter. The pulmonic valve is normal in appearance. No pericardial/pleural effusion or cardiac masses are seen.

AGE

10 years

WEIGHT

74lbs

CARDIAC CHART

INTERPRETED BY

Maggie Machen Lamy,
DVM, DACVIM
(Cardiology)

CANINE CARDIAC PARAMETERS	MR VMAX (m/s)	TR VMAX (m/s)	LA/AO (Boon method)	LA/AO (Heart Base; Swe)	FS (%)	EF (%)	EPSS (cm)
NORMAL PARAMETER	4.5-5.5	<2.7	1.3	<1.6	28-40	40-100	<0.6
PATIENT	NM	NA	NM	2.2	51	83	NM
CANINE CARDIAC PARAMETERS	HR (BPM)	AV VMAX (m/s)	PV MAX (m/s)	BODY WEIGHT (kg)	LA 2D short axis Base view (cm)	LVIDd Avg; 2D and m-mode short axis (cm)	LVIDs Avg; 2D and m-mode short axis (cm)
NORMAL PARAMETER	50-100	0.7-1.7	0.7-1.6	BELOW	BELOW	BELOW	BELOW
PATIENT	NM	1.3	NM	33.6	4.8	4.9	2.9
*Normal chamber parameters expressed as a mean value (SD)				3	1.27 (5.3)	2.46 (2.46)	1.36 (5.5)
BODY WEIGHT DEPENDENT PARAMETERS				5	1.40 (4.5)	2.74 (5.2)	1.60 (4.7)
*Note: All measurements based upon multi-modal images and methods. An average value is reported.				10	1.50 (3.8)	3.27 (3.5)	2.06 (3.1)
				15	1.83 (2.0)	3.71 (2.4)	2.43 (2.1)
				20	2.02 (1.9)	4.14 (2.2)	2.80 (2.0)
				25	2.18 (2.4)	4.48 (2.9)	3.10 (2.5)
				30	2.33 (3.3)	4.83 (3.9)	3.39 (3.4)
				35	2.48 (4.3)	5.17 (5.0)	3.69 (4.5)
				40	2.62 (5.2)	5.48 (6.1)	3.96 (5.4)
				50	2.88 (7.1)	6.07 (8.3)	4.46 (7.4)

Adapted from June Boon, Veterinary Echocardiography, 1998
Rishniw M and Hollis NE, J Vet Intern Med 2000; 14:429-435
Hansson et al, Vet Rad and Ultrasound 2002
Bonagura et al. Echocardiography: principles of interpretation, Vet Clin North Am 15:1177, 1995

IMAGING PERFORMED BY

Dana Alterman,
RDCS, LVT

HOSPITAL NAME

Eubank Animal Clinic

REFERRING VET

Dr. Smith

INVOICE

26436

DATE

9/19/22



PATIENT

Teddy Pereira

SPECIES

Canine

BREED

Australian Shepherd

SEX

Male Neutered

AGE

10 years

WEIGHT

74lbs

INTERPRETED BY

Maggie Machen Lamy,
DVM, DACVIM
(Cardiology)

IMAGING PERFORMED BY

Dana Alterman,
RDCS, LVT

HOSPITAL NAME

Eubank Animal Clinic

REFERRING VET

Dr. Smith

INVOICE

26436

DATE

9/19/22

INTERPRETATION OF THE FINDINGS & FURTHER RECOMMENDATIONS

Chronic degenerative valve disease causing severe mitral regurgitation. The LA is significantly dilated indicating a high risk for clinical signs going forward. Mild pulmonary hypertension is noted, which is likely secondary to chronic LA pressure elevation. No additional concurrent issues such as systolic dysfunction are documented. The ECG is unremarkable with a normal sinus rhythm.

Panting is highly non-specific in the absence of concurrent labored breathing or a cough. Baseline chest radiographs are strongly recommended to screen for early decompensation.

With this degree of left heart changes, the risk for spontaneous congestive heart failure is elevated and cardiac supportive medications are indicated as below. A weak diuretic (spironolactone) is included given high risk for decompensation in the future. Assessment of progression in the future will help predict long term outcome, however prognosis is guarded at this stage (late B2). Unfortunately, the patient will always be at risk for recurrent CHF, development of arrhythmias/LA tear, syncope and/or sudden death in the future.

Close monitoring for development of associated clinical signs (development of a cough, labored breathing, exercise intolerance or worsening collapse episodes) is recommended. Monitoring of sleeping breathing rates is recommended as the best way to screen for CHF at home.

Elective anesthesia is not advised, as there is high risk for complication. If necessary, cardiac protective drug choices (opioid/benzodiazepine premedication, propofol or alfaxalone induction, iso or sevoflurane gas) are recommended. Pre-oxygenate for 5-10 minutes prior to induction and recover in O2 cage. Monitor for arrhythmias, hypotension, and hypoxia both intra and post-operatively and intervene as necessary. Moderate IV fluid restriction is recommended to avoid fluid overload. Avoid heart rate stimulating drugs such as atropine unless clinically indicated.

Omega fatty acid supplementation and mild salt restriction may also be of some long-term benefit.

PLAN

A screening BP and CXR are recommended. Administer Pimobendan 0.3mg/kg PO q12h. Institute ACE-I (benazepril or enalapril) 0.5mg/kg PO q12h. Institute spironolactone 1-2mg/kg PO q12h.

Monitor renal values in 1-2 weeks, then every 3-4 months lifelong to ensure tolerance of medications.

A recheck echocardiogram is recommended in 4-6 months to screen for progression, sooner if clinical signs arise.



PATIENT

Teddy Pereira

SPECIES

Canine

BREED

Australian Shepherd

SEX

Male Neutered

AGE

10 years

WEIGHT

74lbs

INTERPRETED BY

Maggie Machen Lamy,
DVM, DACVIM
(Cardiology)

**IMAGING
PERFORMED BY**

Dana Alterman,
RDCS, LVT

HOSPITAL NAME

Eubank Animal Clinic

REFERRING VET

Dr. Smith

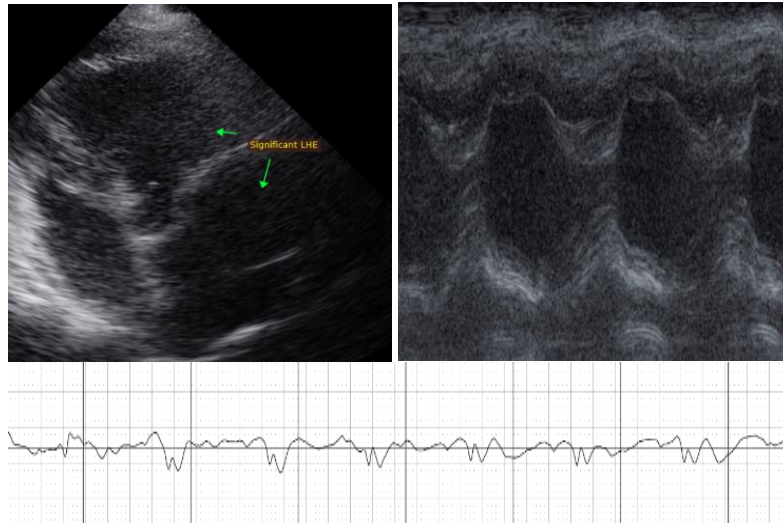
INVOICE

26436

DATE

9/19/22

IMAGES



The information and recommendations provided are based on the images presented by the referring veterinarian. No evaluation can be communicated regarding pathology that was not visible in the image/video clips provided.

Thank you for this referral. This report was generated using transcription software, and minor dictation errors may be present. If the clinical or image interpretation does not parallel your findings or if I can be of any further assistance, please contact me.

Maggie Machen Lamy, DVM
Diplomate of the American College of Veterinary Internal Medicine (Cardiology)
info@sonopath.com